



Breast Surgery

Preliminary Report

A Preliminary Assessment of the Predictability of Fat Grafting to Correct Silicone Breast Implant-Related Complications

Marcos Sforza, MD; Katarina Andjelkov, MD, PhD;
Renato Zaccheddu, MD; Rodwan Husein; and Connor Atkinson

Aesthetic Surgery Journal
2016, 1–9
© 2016 The American Society for
Aesthetic Plastic Surgery, Inc.
Reprints and permission:
journals.permissions@oup.com
DOI: 10.1093/asj/sjw060
www.aestheticsurgeryjournal.com
OXFORD
UNIVERSITY PRESS

Abstract

Background: Fat grafting in breast augmentation surgery is becoming increasingly popular and is allowing surgeons to fill the gaps that implant augmentation alone cannot. However, one current issue surrounding fat grafting is resorption.

Objectives: In this prospective study, the authors present their experience of fat grafting and resorption in 26 patients who had fat transfer to correct deformities or asymmetries following primary breast enlargement surgery.

Methods: The fat utilized was harvested and processed using the Puregraft system. Fat grafting was performed until the problem was visually corrected, followed by an additional 30% overcorrection. Photographs were taken preoperatively and 1 year postoperatively, and analyzed utilizing cloud-based 3-dimensional imaging software to measure the breast volumes and calculate 1-year resorption rates. Both patients and physicians were asked to rate their satisfaction.

Results: The total volume of fat transferred ranged from 160 cc to 360 cc, with an average of 280 cc per procedure. The absolute volume of tissue resorption showed considerable variation (median, 42.6 mL; range, 5.5–62 mL). However, there was a very close correlation between the volume resorbed and the volume implanted: the more volume injected, the more volume absorbed. When expressed as a percentage of implanted tissue, the resorption rate was $27.5 \pm 0.8\%$ (mean \pm standard deviation) with a very narrow range (25.7%–28.9%). Patients and physicians reported a satisfaction rate of “excellent” in 83.3% and 75% of cases, respectively.

Conclusions: At 1 year, 25.7% to 28.9% of the injected fat had been resorbed in a predictable, reproducible, and effective manner.

Level of Evidence: 4



Accepted for publication February 29, 2016.

Autologous fat tissue is widely utilized today as a soft-tissue filler in both small- and large-volume applications.¹ However, a review of the literature indicates that there is considerable variability in tissue retention with autologous fat tissue, leading to unpredictable outcomes.^{2,3} These differences in retention rates are generally believed to be caused by a combination of donor-intrinsic factors (eg, age, smoking history, exposure to radiotherapy at the implant site, etc.), differences in techniques utilized for tissue harvest and implantation, and the presence of components within the graft that can negatively impact retention (eg, lipid from damaged adipocytes, blood cells, and debris). Analysis of the factors affecting retention has been generally impaired by the paucity of robust,

Dr Sforza is an Examiner for the Royal College of Surgeons of Edinburgh. Dr Andjelkov is a plastic surgeon in private practice in Belgrade, Serbia. Dr Zaccheddu is a Plastic Surgeon at Dolan Park Hospital in Bromsgrove, United Kingdom. Mr Husein and Mr Atkinson are Medical Students, Leeds Medical School, Leeds, United Kingdom.

Corresponding Author:

Prof Marcos Sforza, Dolan Park Hospital, Stoney Lane, B60 1LY, Bromsgrove, United Kingdom.
E-mail: marcos@marcosforza.com

Presented at: the International Federation for Adipose Therapeutics and Science (IFATS) meeting in October 2012 in Québec City, Québec, Canada (in part); and at the IMCAS meeting in January 2015 in Paris, France, and at The Aesthetic Meeting 2015 in Montréal, Québec, Canada (in full).

quantitative data focused on a single clinical application. In this article, we present a prospective study of 26 patients who underwent fat injections to correct deformities or asymmetries following breast enlargement surgery with silicone implants, in a total of 50 breasts. In this study, patients received moderate- to large-volume fat grafts that were harvested, processed, and implanted according to standardized methods, and quantitative 3-dimensional (3D) analysis was applied to obtain reproducible volume-retention data. The results demonstrate that this standardized approach provides highly predictable retention outcomes, wherein the percentage of implanted tissue that is lost falls within a very small range and is independent of the absolute volume of tissue implanted.

METHODS

Over a period of 12 months from January to December 2012, 26 female patients presented to our private practice plastic surgery clinic with self-described unsatisfactory results following breast enlargement surgery at various outside plastic surgery clinics. This study had no exclusion criteria and took all patients consecutively. The corresponding author (M.S.) divided the patients' unsatisfactory results into two general groups: asymmetries (difference in volume, $n = 17$) and deformities (difference in shape, rippling, capsular contracture, double bubble, $n = 9$). The corresponding author (M.S.) performed all of the surgeries. Patients were evaluated and prospectively offered autologous fat transfers, as opposed to breast implant replacement, to correct their dissatisfaction. All patients were nonsmokers and all patients had a body mass index (BMI) within the normal weight limits. No patients had material comorbidities such as diabetes or high blood pressure. No patients had implant replacement surgery or any other associated surgeries together with the fat grafting procedure. Fat tissue was harvested with a 60 mL Luer Lock syringe (Becton Dickinson, Franklin Lakes, NJ) from the abdominal area utilizing a 2.4 mm cannula (Sforza Harvester, Tulip Medical Products, San Diego, CA) and processed utilizing the Puregraft system (Puregraft LLC, Solana Beach, CA). After the preparation of the tissue, a single needle-puncture incision was made near the area to be treated. The surgeon applied the fat in a fanlike movement with a 20 mL cc Luer Lock syringe attached to a 0.9 mm cannula (Tulip Injector, Tulip Medical Products), aiming to apply 1 mL of fat per passage. Fat grafting was performed until the problem was visually corrected, as determined by the operating surgeon. A narrative video of a similar procedure may be viewed as Supplementary Material at www.aestheticsurgeryjournal.com.

The volume injected was noted, and then an additional 30% overcorrection was grafted, taking into consideration historically published low absorption rates. The total volume of fat transferred ranged from 160 cc to 360 cc, with

an average of 280 cc per procedure, with a maximum volume per breast registered in this series of 220 mL.

All surgeries were performed in a specialized plastic surgery hospital with the patients receiving a general anesthetic. All patients signed an informed consent form for the described procedure. All patients had a single dose of 1.5g of cefuroxime as a prophylactic antibiotic 1 hour before the surgery started. All patients had compression socks (Preventx, Loughborough, United Kingdom) and a prophylactic pneumatic deep vein thrombosis (DVT) system (Flowtron, Huntleigh Healthcare, Eatontown, NJ) during the procedure. However, no chemical prophylaxis for DVT was given, according to hospital policy for short procedures (less than 2 hours). Patients were discharged with compression garments on the harvested area but only soft dressings on the grafted areas to avoid compression of the transferred fat.

Photographs were taken preoperatively, and 1 year postoperatively. These photographs served as a basis for a satisfaction questionnaire in which both patients and independent physicians (three board-certified plastic surgeons) were asked to rate their satisfaction. In addition to the satisfaction questionnaire, the photographs were subsequently analyzed utilizing cloud-based 3D imaging software (Crisalix, Lausanne, Switzerland). The 3D analysis provided us with the volume of the breast both preoperatively and postoperatively, allowing us to calculate 1-year

Table 1. Information on Patient Demographic and Complications

Number of patients	26
Number of breasts grafted	50
Age range (years)	19-32
Age average \pm SD (years)	24 \pm 3.48
Gender	All female
Infections	0 (0%)
Seroma	0 (0%)
Oil cysts	0 (0%)
Hematoma	0 (0%)

SD, standard deviation.

Table 2. Tissue Volume Implanted per Breast

Number of breasts	50
Mean \pm SD	148 \pm 48 mL
Median	155 mL
Range	20-220 mL

SD, standard deviation.

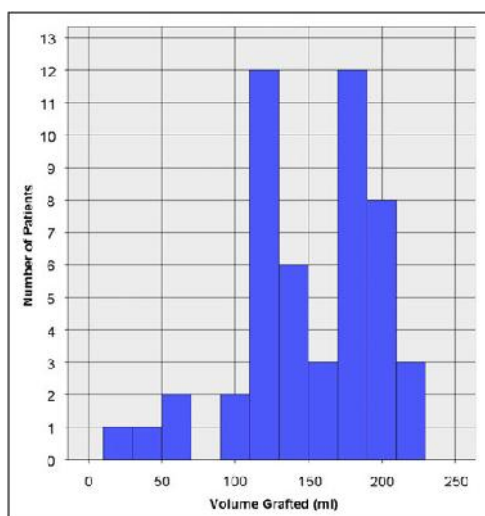


Figure 1. The data of the distribution volume of fat grafted.

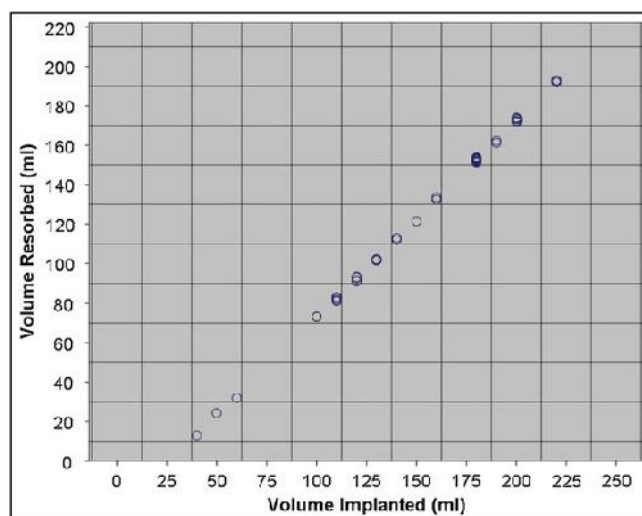


Figure 2. There was a close correlation between the volume resorbed and the volume implanted.

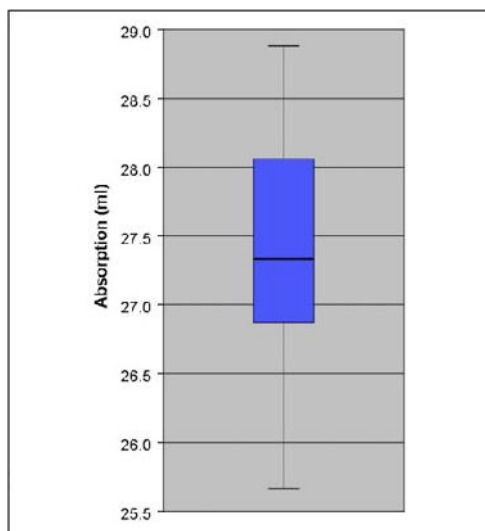


Figure 3. The percentage of resorption rate demonstrates a very narrow range (25.7% to 28.9%).

absorption rates. It should also be noted that none of the patients in this study received fat grafts in an area with known underlying pathology or any other clinical condition that might render the area to be more hostile to implanted tissue. For example, none of the patients had received previous radiotherapy or were implanted in an area that had considerable fibrosis and/or physical evidence of impaired vascularity.

RESULTS

The mean age of the patients was 24 years (standard deviation [SD], ± 3.48 years; range, 19-32 years). Additional

information about patient demographics and complications is in Table 1.

Patient and Physician Satisfaction

All 26 patients completed a 1-year satisfaction questionnaire (Appendix A, available online at www.aestheticsurgeryjournal.com). This questionnaire is the standard patient satisfaction evaluation form that we utilize in our practice, but we acknowledge that the questionnaires were not completed anonymously. All physician satisfaction questionnaires were also completed at 1 year (Appendix B, available online at www.aestheticsurgeryjournal.com). At the 1 year time point, patients reported a satisfaction rate of “excellent” in 84.6% ($n = 22$) of cases, “good” in 11.5% ($n = 3$), and “fair” in 3.8% ($n = 1$). The 1-year physician satisfaction rated as “excellent” in 73.1% of cases ($n = 19$), “good” in 19.2% ($n = 5$), and “fair” in 7.7% ($n = 2$) of cases. During the follow-up period, no patients had evidence of infections, seromas, hematomas, or oil cysts formation after fat grafting. No imaging control on the breasts was performed, because the injections were subcutaneous under a thin skin and the clinical examination of the patients was sufficient to exclude the presence of cysts or lumps in the injected area. In all patients, a successful correction of the presenting problem was achieved without complications, as confirmed in the physicians’ questionnaire.

Retention Volume

Data for the volume of fat grafted are shown in Table 2 and Figure 1. As displayed in Figure 1, the volume of fat grafted was not normally distributed; the vast majority of cases

Table 3. A *t* test Comparing Absorption Between Grafted Volume <150 mL and >150 mL of Fat

Independent Samples Test				
		<i>t</i> test for Equality of Means		
		Sig. (2-tailed)	Mean Difference	Std. Error Difference
Absorption	Equal variances assumed	.312	.23846	.23340
	Equal variances not assumed	.313	.23846	.23381

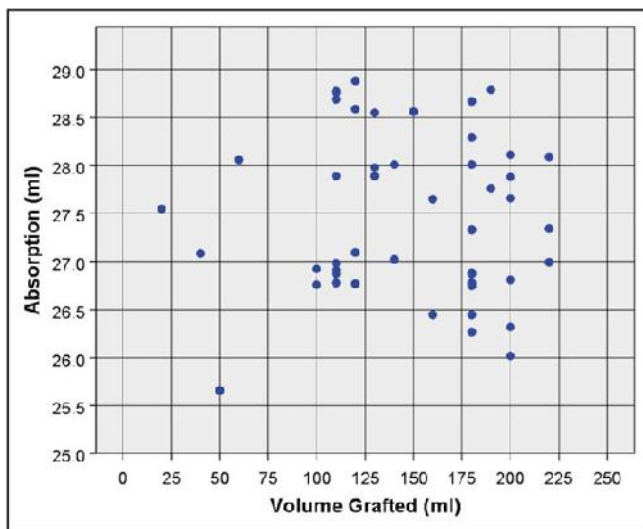


Figure 4. The percentage of volume lost was independent of the absolute volume implanted.

(46/50) involved transfer of ≥ 100 mL of tissue. The median volume grafted per breast was 155 mL.

The absolute volume of tissue resorption showed considerable variation (median, 42.6 mL; range, 5.5-62 mL). However, there was a very close correlation between the volume resorbed and the volume implanted (Figure 2). When expressed as a percentage of implanted tissue, the resorption rate was $27.5 \pm 0.8\%$ (mean \pm SD), with a very narrow range (25.7% to 28.9%) (Figure 3). The percentage of volume lost was independent of the absolute volume implanted (Figure 4; slope of the curve = 0.0006; $R^2 = 0.00115$). The same results were observed by comparing the absorption rate between different chosen volumes of grafted tissue. Tables 3 and 4 show the result of a *t* test comparing the mean absorption rate between grafted volume less than and greater than 150 mL and between grafted volume less than and greater than 120 mL, respectively. The hypothesis was a common mean absorption rate. In neither of these cases were we able to reject the hypothesis of common mean. This is even more clearly observed

Table 4. A *t* test Comparing Absorption Between Grafted Volume <120 mL and >120 mL of Fat

Independent Samples Test			
		<i>t</i> test for Equality of Means	
		95% Confidence Interval of the Difference	
		Lower	Upper
Absorption	Equal variances assumed	-.23081	.70773
	Equal variances not assumed	-.23185	.70877

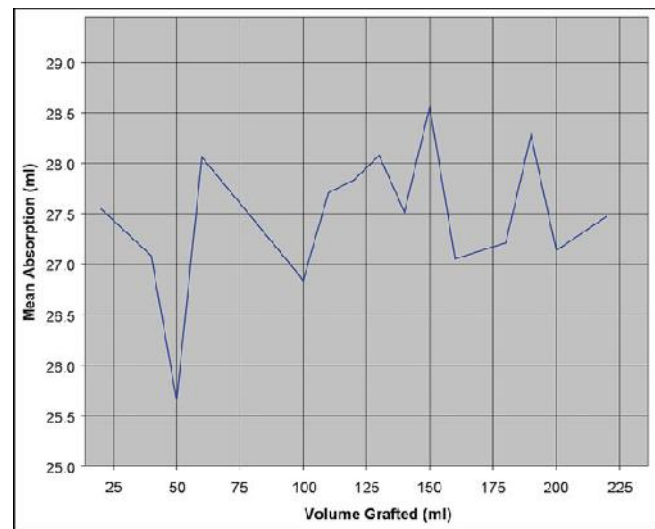


Figure 5. The absorption rate has minimal variability and increases or decreases independently from the grafted volume.

in Figure 5, where we can verify that the mean absorption rate for different grafted volume levels. Again, we can see that the absorption rate has minimal variability and that it increases or decreases independently from the grafted volume. The same results can be concluded from comparing the absorption rate between sections of grafted volume. There were no significant differences on the absorption rates among the groups, allowing us to say that the predictability of the fat survival was constant independently of the original deformity. Therefore, the division of the groups became relevant only from a demographics perspective, allowing us to acknowledge the different patients studied in this article. There was no clinically noticeable change on the patients' BMI range 1 year postoperatively.

DISCUSSION

This study employed a highly sensitive, objective, and quantitative assessment of volume to examine the rate of tissue resorption following autologous fat grafting. The

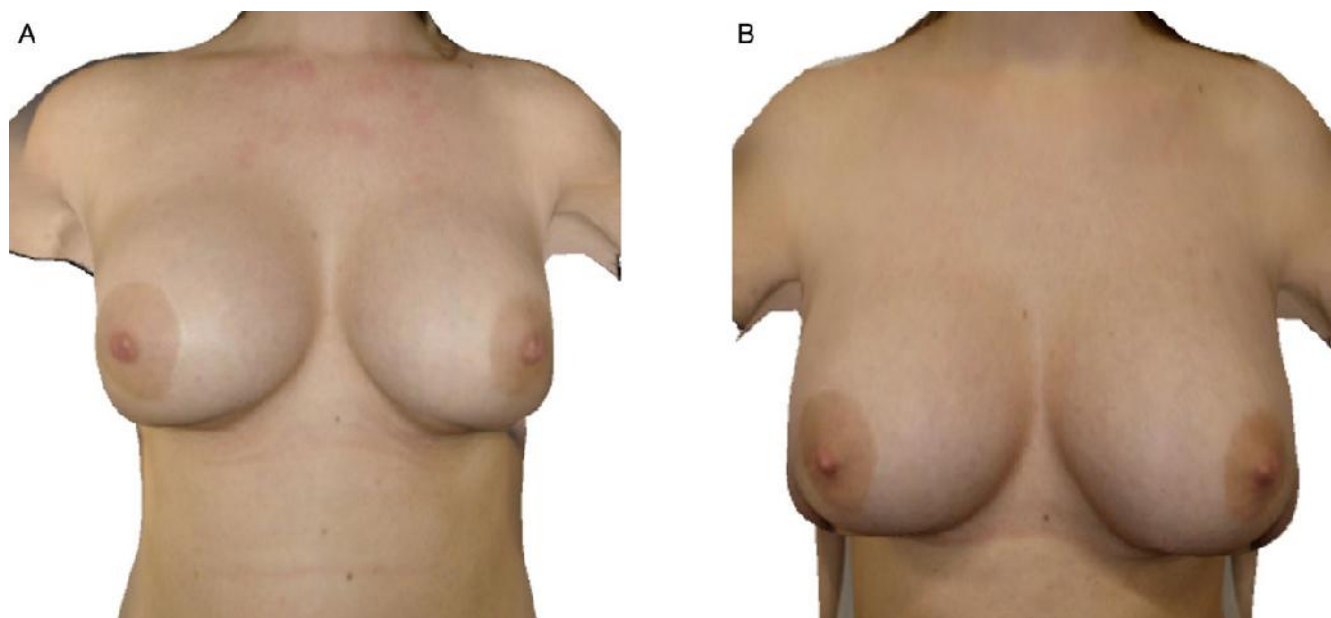


Figure 6. (A) This 25-year-old woman is shown when she presented with asymmetric breasts and (B) 1 year postoperatively. Preoperative and postoperative 3D images were generated with Crisalix.

data demonstrate that a standardized tissue harvest, method of processing, and implantation approach mitigate the vast majority of variability and unpredictability commonly ascribed to autologous fat grafting, such that the volume of tissue implanted is the primary determinant of the absolute amount of tissue volume lost. We acknowledge that despite the fact that there were no exclusion criteria to this study, the cohort was very homogeneous and rather young, probably because of the very nature of the original procedure. Some could see this as a favorable factor to improve graft intake. There are no conclusive studies that compare resorption rates according to patient age. Therefore, a statement to advocate this theory will also lack scientific support. The standardized procedure seems to be the best explanation so far.

We acknowledge that the high satisfaction rate encountered in both the patients' and surgeons' questionnaires have a limitation because they were not filled out anonymously. Nevertheless, the independent surgeons who were evaluators never met the patients, which minimizes such bias.

Volume Analysis

Perhaps the most accurate method of measuring fat retention is to excise the fat and weigh the specimen, which is the method utilized in animal studies. Because this is not possible in human studies, different types of image-based measures are available. Although the quality of the 1-year clinical

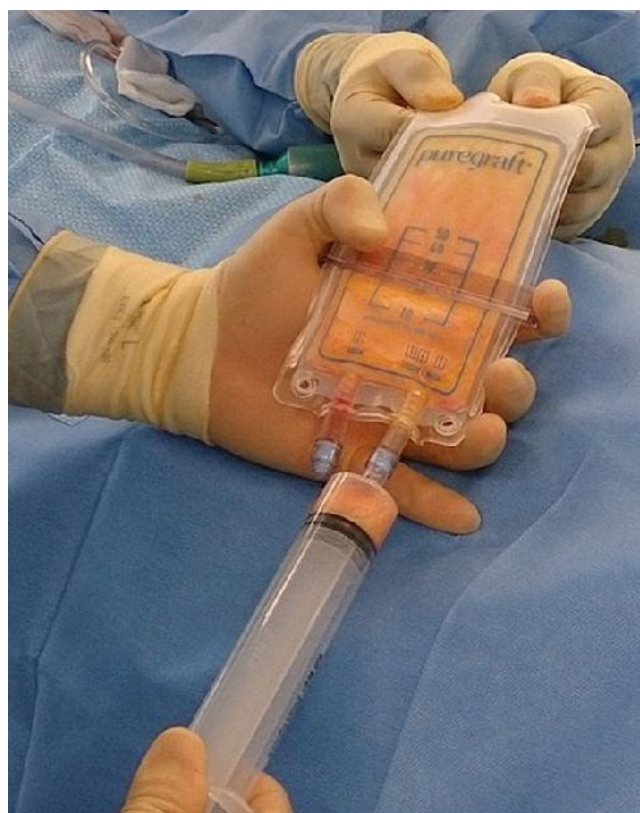

Figure 7. This intraoperative photograph demonstrates that the Purecraft allowed us to remove free lipid, white blood cells, and red blood cells at large.

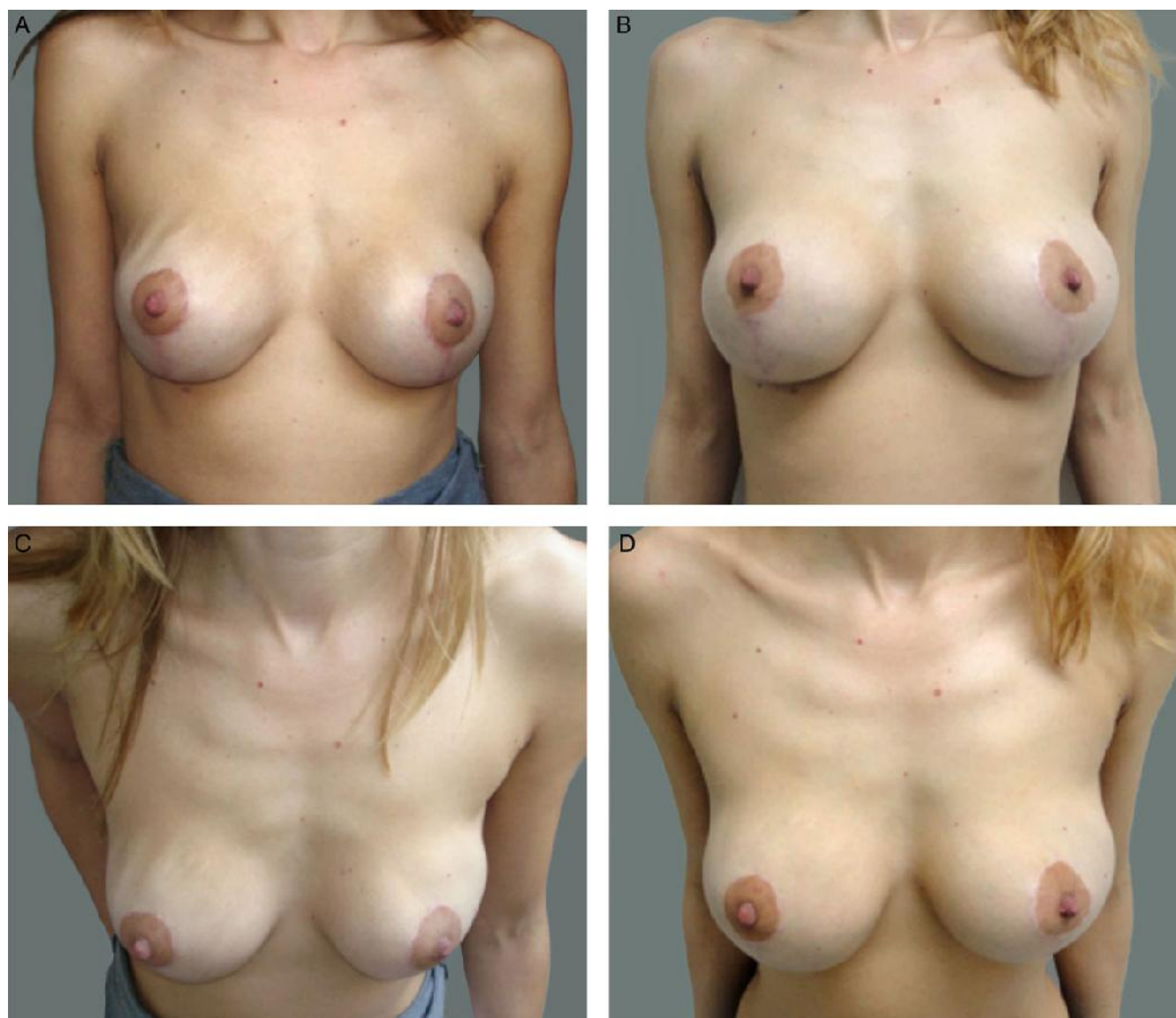


Figure 8. (A, C) Preoperative photographs of this 31-year-old woman with a previous mastopexy with implants in a subpectoral pocket. She was referred to us from another hospital because of rippling at the upper pole. (B, D) She is shown 1 year after 180 cc of fat was grafted in each breast. (C) Another perspective of the severe rippling that occurred even with a subpectoral pocket.

outcomes are clear with routine examination of the patients, the quantitative analysis of retained volume utilizing a validated 3D imaging software is fundamental to support the statistical significance of our results. The processing of uploading photographs by the surgeon is fast (less than 10 minutes) and therefore can readily obtain measurements. This system utilizes a physics-based simulation (Voxel approach), in which small cubes are utilized to fill the internal breast to model the internal breast tissue (Figure 6). Although there are several published methods of quantitative volume assessment, this particular approach was chosen because of its sensitivity to real volume change. In a study published by de Heras Ciechomski et al,⁴ the authors showed that when utilizing this method, there is a mean

reconstruction error between 2 mm and 4 mm for both the left and right breasts. However, by taking into account the large 90° angle between the frontal and lateral photographs utilized in the reconstruction, the observed maximum surface error appeared small. Furthermore, the maximum surface error is less than the motion artifacts caused by breathing excursions and the small changes caused by patient repositioning when laser or optical scan devices are utilized. Their study verifies the reliability and accuracy of the method utilized in this article.⁴

We recognize that in utilizing such a method, there are inherent limitations. However, the same limitations apply to any study utilizing acquired images to reconstruct a 3D model. In their facial fat grafting study, Gerth et al⁵

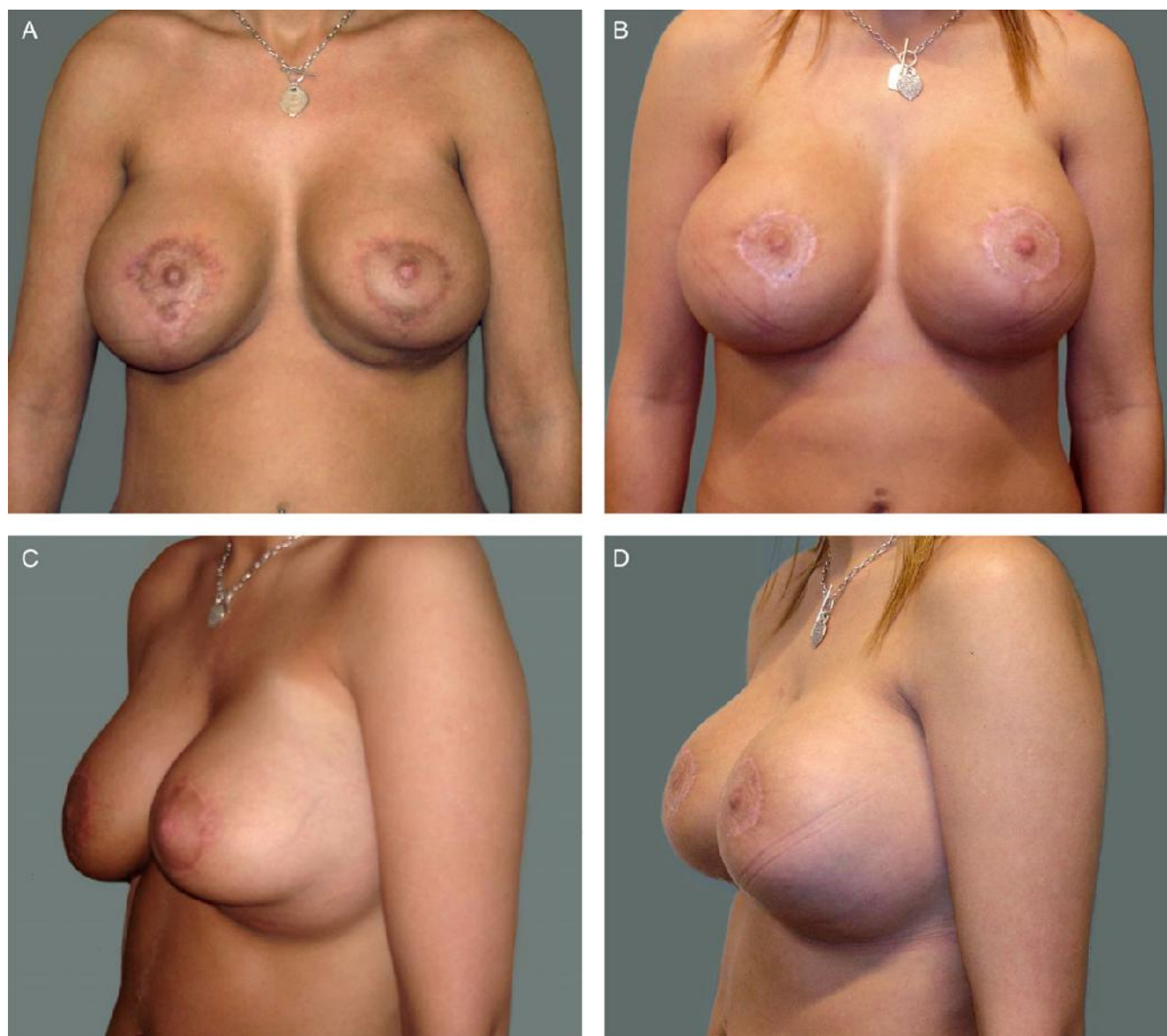


Figure 9. (A, C) Preoperative photographs of this 29-year-old woman who had previous breast mastopexy implants in a subpectoral pocket and four revisional surgeries. She was referred to us from a colleague who believed he had exhausted his options with this patient, who now presented with a severely shaped deformity. The preoperative oblique view (C) demonstrates a severe “double bubble” deformity. (B, D) She is shown 1 year after having 200 cc of fat grafted on the left breast and 100 cc of fat grafted on the right breast. This patient refused that any kind of pocket or implant be changed, and she even refused scar revisions after the previous surgeries. She made it clear that she would only accept a minimally invasive procedure to improve the shape of her breasts. This case demonstrates that fat grafting can be utilized to correct severe deformities caused by a previous breast surgery.

acknowledged that the accuracy of the data obtained with the Vectra 3D imaging system (Canfield, Fairfield, NJ) were user dependent and that errors in volume measurement could be introduced.

Some studies consider magnetic resonance imaging (MRI) a potentially better method for volumetric measurements.⁶⁻⁸ However, MRI is expensive, time-consuming, and not easily accessible, especially in facilities that specialize in plastic surgery or outpatient clinics.

After the system generates the 3D image, it identifies the landmark limits of the breast and upon request provides the volume of the breast in a very simple manner, similar to other 3D devices such as the previously mentioned Vectra 3D system. Several studies already demonstrated that breast augmentation simulations correlate highly with positive surgical outcomes and increased patient scheduling in specific practices together with higher productive rates.^{8,9} In our study, 3D simulations were only utilized as a measurement tool, but

their efficacy should lead to other studies in which 3D simulations will also be incorporated in the surgical planning.

The virtual method of analysis utilized in this study eliminated the need for capital investment on hardware, because the technique utilizes a web-based license. Additionally, surgeon-investigators are not limited to a single location or a single point in time to review patient data.

Harvest Methodology

We believe that utilizing a multi-hole cannula, designed specifically for this study, played an important role in explaining the results. This new cannula is designed with 20 mm x 1 mm holes arranged in a special layout to facilitate bidirectional harvest. The holes are designed with an elevated 1 mm microport in one end, and the ports at the other end are machined with 60-degree cutting edges.

In addition, the asymmetric disposition of the holes in a helical pattern ensure that all holes see an identical aspiration pressure. The net effect of the number of holes, in combination with the layout, is to aspirate tissue at the same time, providing more fat harvested with less passages, thus ultimately promoting less trauma to the fat and adjacent tissue. By design, the harvested grafted particles were always smaller than 1 mL. This information is still only conjectural, because there are no scientific studies to prove this theory. However, it is important to highlight that there are several studies demonstrating that larger fat particles tend to have higher absorption rates.^{11,12}

Tissue Processing

This study employed a standardized method for preparing the graft before injection. We utilized the Puregraft system to remove contaminants such as free lipid and red blood cells. In a recent paper by Zhu et al,¹³ autologous fat grafts prepared with this sterile, single-use approach proved to be far more effective at removing free lipid, white blood cells, and red blood cells when compared with alternative approaches such as centrifugation. Specifically, the authors reported that free lipid comprised only $0.5\% \pm 0.1\%$ of the volume of the graft when processed with the Puregraft system, compared with $12.6 \pm 1.6\%$ of the volume when the same tissue was processed by centrifugation (Figure 7).

Tissue Injection

All fat was grafted utilizing identical, small injectors (0.9 mm), without any technical difficulties. As extensively put forth by Coleman,¹⁴ the use of multiple injections with small volumes per passage is fundamental for a lower resorption rate. The reader is also reminded that none of the patients received grafts into hostile recipient areas. This is noteworthy, because it is reasonable to expect a greater

percentage resorption at such sites in the absence of approaches directed at enhancing retention such as enrichment with stromal vascular fraction cells^{15,16} (Figures 8 and 9; Supplementary Figures 1-3).

Patient Messaging

Results from this investigation can aid in managing patient expectations before performing a grafting procedure. Regardless of the volume injected, a patient's perspective on the retained volume will be masked in part by initial swelling and edema. However, the fact that smaller grafts will have a correspondingly small absolute volume of resorption will be difficult to perceive. At the other end of the spectrum, the larger absolute volume of resorption following implantation of a larger graft will be more visually apparent leading to an increased likelihood that the patient will notice the change and have a perception of poor graft retention. Armed with this knowledge, the surgeon can prospectively inform their patients that perception will vary by volume, thus fostering an enhanced comprehension and avoiding misunderstood expectations.

CONCLUSIONS

In summary, careful attention to standardization of tissue collection, processing, and implantation can lead to a high predictability of retention of autologous fat grafts in patients with a healthy recipient tissue bed. This predictability can be expected to improve patient satisfaction.

Supplementary Material

This article contains supplementary material located online at www.aestheticsurgeryjournal.com.

Disclosures

The authors declared no potential conflicts of interest with respect to the research, authorship, and publication of this article.

Funding

The authors received no financial support for the research, authorship, and publication of this article.

REFERENCES

1. Kaufman MR, Bradley JP, Dickinson B, et al. Autologous fat transfer national consensus survey: trends in techniques for harvest, preparation, and application, and perception of short- and long-term results. *Plast Reconstr Surg*. 2007;119(1):323-331.
2. Kaufman MR, Miller TA, Huang C, et al. Autologous fat transfer for facial recontouring: is there science behind the art? *Plast Reconstr Surg*. 2007;119(7):2287-2296.
3. Chan CW, McCulley SJ, Macmillan RD. Autologous fat transfer—a review of the literature with a focus on breast

- cancer surgery. *J Plast Reconstr Aesthet Surg*. 2008;61(12):1438-1448.
4. de Heras Ciechowski P, Constantinescu M, Garcia J, et al. Development and implementation of a web-enabled 3D consultation tool for breast augmentation surgery based on 3D-image reconstruction of 2D pictures. *J Med Internet Res*. 2012;14(1):e21.
 5. Gerth DJ, King B, Rabach L, et al. Long-term volumetric retention of autologous fat grafting processed with closed-membrane filtration. *Aesth Surg J*. 2014;34(7):985-994.
 6. Gosain AK, Klein MH, Sudhakar PV, Prost RW. A volumetric analysis of soft-tissue changes in the aging midface using high-resolution MRI: implications for facial rejuvenation. *Plast Reconstr Surg*. 2005;115(4):1143-1152; discussion 1153-1155.
 7. Darcy SJ, Miller TA, Goldberg RA, et al. Magnetic resonance imaging characterization of orbital changes with age and associated contributions to lower eyelid prominence. *Plast Reconstr Surg*. 2008;122(3):921-929; discussion 930-931.
 8. Creasman CN, Mordaunt D, Liolios T, et al. Four-dimensional breast imaging, part I: introduction of a technology-driven, evidence-based approach to breast augmentation planning. *Aesthet Surg J*. 2011;31(8):914-924.
 9. Creasman CN, Mordaunt D, Liolios T, et al. Four-dimensional breast imaging, part II: clinical implementation and validation of a computer imaging system for breast augmentation planning. *Aesthet Surg J*. 2011;31(8):925-938.
 10. Wysong A, Joseph T, Kim D, et al. Quantifying soft tissue loss in facial aging: a study in women using magnetic resonance imaging. *Dermatol Surg*. 2013;39(12):1895-1902.
 11. Sommer B, Sattler G. Current concepts of fat graft survival: histology of aspirated adipose tissue and review of the literature. *Dermatol Surg*. 2000;26(12):1159-1166.
 12. Kato H, Minoda K, Eto H, et al. Degeneration, regeneration, and cicatrization after fat grafting: dynamic total tissue remodeling during the first 3 months. *Plast Reconstr Surg*. 2014;133(3):303e-313e.
 13. Zhu M, Cohen SR, Hicok KC, et al. Comparison of three different fat graft preparation methods: gravity separation, centrifugation, and simultaneous washing with filtration in a closed system. *Plast Reconstr Surg*. 2013;131(4):873-880.
 14. Coleman SR. Chapter 26: Structural lipoaugmentation. In: Narins RS, ed. *Safe Liposuction and Fat Transfer*. Boca Raton, FL: CRC Press; 2003:409-424.
 15. Zhu M, Zhou Z, Chen Y, et al. Supplementation of fat grafts with adipose-derived regenerative cells improves long-term graft retention. *Ann Plast Surg*. 2010;64(2):222-228.
 16. Pérez-Cano R, Vranckx JJ, Lasso JM, et al. Prospective trial of adipose-derived regenerative cell (ADRC)-enriched fat grafting for partial mastectomy defects: the RESTORE-2 trial. *Eur J Surg Oncol*. 2012;38(5):382-389.